

The muscles and skin are then closed up, the skin usually being closed with an invisible dissolvable stitch obviating the need for stitch removal. The facet joints and disc are left intact in this procedure so it does not make the spine unstable.

## The Hospital Stay

Normally you will be admitted the day before or on the morning of your operation. After surgery you will be encouraged to get out of bed and up and about as soon as possible. Often you will be seen by the physiotherapist who will help with mobility and posture immediately post-operatively. The majority of patients are well enough to go home two or three days after their operation.

## Post Operative Course

When you go home you will need to take it easy for a few weeks. You should keep the wound dry for a week so it is probably best to shower around it for the first few days. You should get back to walking as soon as possible and do a couple of walks every day. Swimming is also good exercise once you are a bit more mobile. Driving (as either a driver or passenger) can be a bit uncomfortable for a while so try and keep out of the car for a few weeks. Also try and avoid any heavy lifting or twisting.

Remember that it may take some time to notice an improvement, and in those patients with rapidly deteriorating symptoms a cessation of the deterioration may be the best that can be achieved.

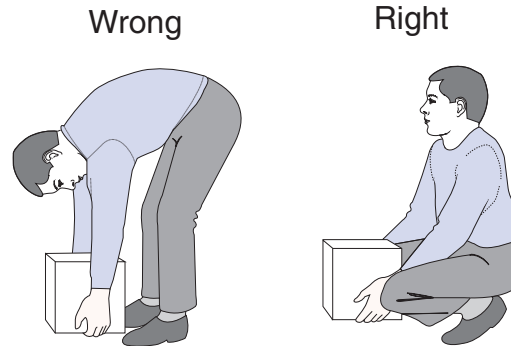
## The longer term

Many patients get a great deal of benefit from this procedure with a marked improvement in their walking distance. Other adjustments which may be of use are.

- Make sure that you are not over your ideal weight.

- Avoid heavy lifting, and if you do lift, ensure that it is done with a straight back and the load as close to you as possible (Fig 7).
- Take regular exercise to maintain muscle strength and suppleness. This will also prevent the weight from creeping up!

Fig. 7

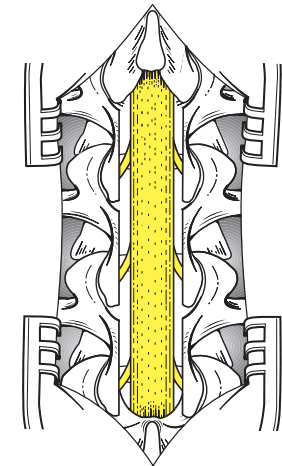


## Follow up

You will be reviewed regularly as an outpatient, first after a few weeks and then at longer intervals until you are fully better.

# Lumbar Laminectomy

## *A Patient's Guide*



Mr R D Ashpole FRCS  
Consultant Neurosurgeon

[www.neurosurgeon.co.uk](http://www.neurosurgeon.co.uk)

## Introduction

This leaflet is intended to reinforce the things that have already been discussed about your back and forthcoming operation.

## Anatomy

The spinal column consists of 24 bones called vertebrae connected together by small joints (called facet joints), and a spongy intervertebral disc. Through the middle of these vertebrae runs a canal in which sits the spinal cord and, at the lower end, the exiting spinal nerves (Figs 1 & 2).

Fig. 1

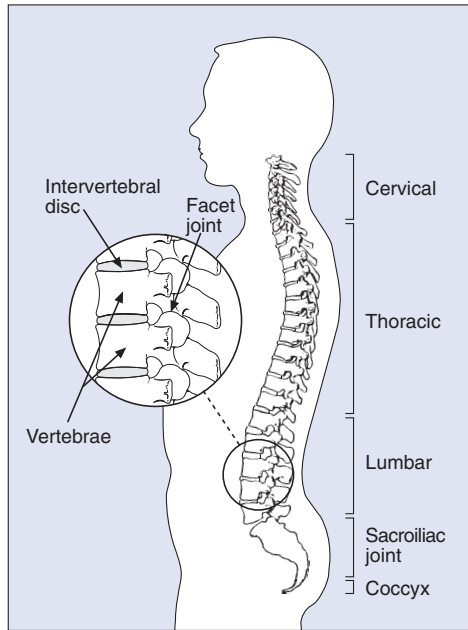
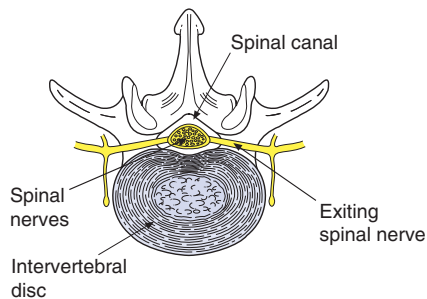
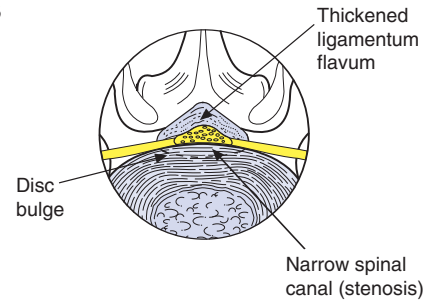


Fig. 2



As we get older this spinal canal gets narrower particularly in the lower back (lumbar region). This is a consequence of some wear and tear in the facet joints causing bony overgrowth in the canal, some thickening of surrounding ligaments and some bulging of the disc. All of these processes narrow the canal thereby decreasing the amount of space for the nerves and their blood supply (Fig 3).

Fig. 3



As a consequence of this, when we exercise or stand for a prolonged period there is insufficient room for the blood supply to the nerves to expand, so those nerves, along with the muscles they supply, cannot work properly. This usually manifests itself as progressive walking difficulties and leg pain, often with pins and needles or tingling in the legs, which settles with rest in a seated position (so called spinal claudication). The diagnosis can usually be confirmed with an MRI (magnetic resonance image) scan which shows the narrowing (stenosis) of the spinal canal.

## Course

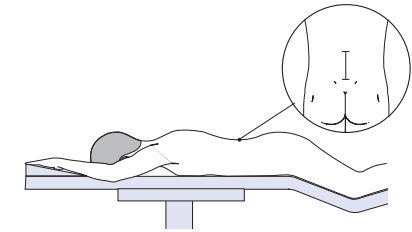
The anatomical changes are really a manifestation of ageing and as such, once present, they do not resolve spontaneously. If the symptoms are severe, disabling and/or worsening it is often necessary therefore to consider a surgical operation.

## Lumbar Laminectomy

This is a common neurosurgical procedure performed under a general anaesthetic (so you are asleep). A short vertical incision is made (about 2-3

inches) in the midline of the lower (lumbar) back (Fig 4). The back of the vertebrae are exposed so that the laminae and spines can be seen (Figs 5 & 6). The lamina and spine is then removed from each of the vertebrae where the canal is tight in order to

Fig. 4



open up the spinal canal (often between one and four need to be thus opened). In essence removing the laminae (hence laminectomy), converts the tight canal into an open gutter giving the nerves and their blood supply more room (Fig 5 & 6).

Fig. 5

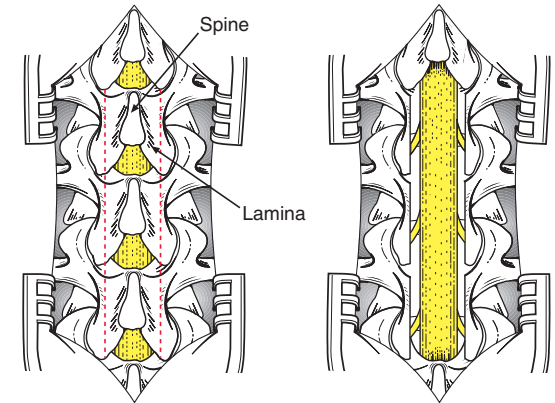


Fig. 6

